

1993

Epidermal Mosaicism and Blaschko's Lines

Celia Moss

S. Larkins

Michael W. Stacey


Old Dominion University, mstacey@odu.edu

A. Blight

P.A. Farndon

See next page for additional authors

Follow this and additional works at: https://digitalcommons.odu.edu/bioelectrics_pubs

 Part of the [Dermatology Commons](#), and the [Developmental Biology Commons](#)

Repository Citation

Moss, Celia; Larkins, S.; Stacey, Michael W.; Blight, A.; Farndon, P. A.; and Davidson, E. V., "Epidermal Mosaicism and Blaschko's Lines" (1993). *Bioelectrics Publications*. 54.

https://digitalcommons.odu.edu/bioelectrics_pubs/54

Original Publication Citation

Moss, C., Larkins, S., Stacey, M., Blight, A., Farndon, P.A., & Davison, E.V. (1993). Epidermal mosaicism and Blaschko's lines. *Journal of Medical Genetics*, 30(9), 752-755.

Authors

Celia Moss, S. Larkins, Michael W. Stacey, A. Blight, P. A. Farndon, and E. V. Davidson

Epidermal mosaicism and Blaschko's lines

Celia Moss, S Larkins, M Stacey, A Blight, P A Farndon, E V Davison

Department of Dermatology, Birmingham Children's Hospital, Ladywood Middleway, Ladywood, Birmingham B16 8ET, UK.
C Moss

Regional Cytogenetics Unit, Birmingham Maternity Hospital, Edgbaston, Birmingham B15 2TG, UK.
S Larkins
M Stacey
E V Davison

Skin Culture Laboratory, Birmingham Accident Hospital, Bath Row, Birmingham B15 1NA, UK.
A Blight

West Midlands Regional Genetic Services, Birmingham Maternity Hospital, Edgbaston, Birmingham B15 2TG, UK.
P A Farndon

Correspondence to Dr Moss.

Received 22 April 1993.
Revised version accepted 3 June 1993.

Abstract

To test the hypothesis that epidermal rather than dermal mosaicism determines Blaschko's lines in hypomelanosis of Ito (HI), we studied the distribution of chromosomal mosaicism in four patients. In two, mosaicism had not been detected in lymphocytes or dermal fibroblasts, but was clearly shown in epidermal keratinocytes; furthermore, the abnormal cell line was confined to the hypopigmented epidermis and the normal epidermis contained only normal cells. Negative findings in the other two patients might be because of mosaicism which was undetected either because it was submicroscopic or because it was present in melanocytes, which have not yet been studied. These preliminary results support the ideas that (1) Blaschko's lines represent single clones of epidermal cells; (2) in patients with HI and severe neurological involvement mosaicism, if detectable, is best shown in keratinocytes; and (3) the cytogenetic defect in epidermal cells may be directly responsible for the failure of pigmentation in HI.

(J Med Genet 1993;30:752-5)

Birthmarks arising from the superficial layer of the skin, epidermal naevi, form striking linear and whorled patterns. Blaschko, a 19th century dermatologist, was struck not only by the strangeness of the patterns, but also by their constancy from one person to the next. He documented the lesions in over 100 patients, transferred them to a plaster of Paris classical statue, and thereby constructed the system known as Blaschko's lines.^{1,2}

We now recognise Blaschko's lines in many different dermatoses, but the cause of this pattern remains speculative. Its constancy in

different disorders suggests that it is a function of normal skin biology rather than a pathological process. Montgomery,³ in 1901, dismissed various anatomical candidates: Blaschko's lines do not correspond to vascular or lymphatic territories, to dermatomes, to Voigt's lines which demarcate areas supplied by the major cutaneous nerve branches, to Langer's lines of skin tension, or to embryological body segments. Montgomery concluded that they reflected the streams or trends of growth of embryonic tissues. This view is still held, unproven but supported by animal studies of melanocyte and keratinocyte migration.^{4,5} This explanation of the orientation of the lines does not, however, explain the patchy nature of the different dermatoses following this pattern. In 1965, Curth and Warburton⁶ suggested that the pigmentation following Blaschko's lines seen in the X linked disorder incontinentia pigmenti reflected functional X chromosome mosaicism (Lyonisation), the normal skin comprising cells in which the normal, paternal X chromosome is active, and the affected skin containing cells in which the abnormal, maternal X chromosome is active. In 1978, Shuster⁷ expressed the more general idea that the whorled appearance of many naevi is "best related to the developmental movement of a clone of cells" and that "susceptibility even to a common disease such as eczema may be focal with a bizarre linear and whorled appearance in a 'clonal' pattern". Happle⁸⁻¹⁰ has developed the hypothesis that disorders following Blaschko's lines reflect genetic mosaicism as a result of Lyonisation or somatic mutation. This idea has been supported by the finding of chromosomal mosaicism in patients with linear dyspigmentation following Blaschko's lines, a condition known as hypomelanosis of Ito (HI) when associated with neurological deficit.¹¹⁻¹⁵ All dermatoses in Blaschko's lines can now be explained on the basis of mosaicism (table 1).

This clonal hypothesis of Blaschko's lines seems so likely to be true that little time has been wasted in trying to prove it. Remarkably, however, experiments in mosaic subjects have totally failed to show what it predicts, namely that one skin type is composed of one cell type, and the other skin type of the other cell type. The hypothesis was first tested in three hermaphrodites, human chimeras with a mixture of 46,XX and 46,XY cells, who had patchy pigmentation with midline demarcation. Cytogenetic studies on fibroblasts cultured from light and dark areas showed a mixture of both cell types in one or both sites.¹⁶ It was next tested in incontinentia pigmenti: X inactivation studies on fibroblasts cultured from light and dark skin showed that the same X chromosome was active in both sites, rather than the normal paternal X in the normal skin and the

Table 1 Linear dermatoses explained on the basis of mosaicism.

| Skin condition | Characteristics of abnormal clone of epidermal cells | Cause of mosaicism |
|---|--|------------------------------------|
| Incontinentia pigmenti Goltz syndrome Chondrodysplasia punctata | Lethal X linked dominant gene | Lyonisation |
| Epidermal naevus Linear porokeratosis CHILD syndrome ILVEN Proteus syndrome McCune-Albright syndrome | Lethal autosomal dominant gene | Half chromatid or somatic mutation |
| Epidermolytic hyperkeratosis Linear Darier's disease Segmental neurofibromatosis Linear psoriasis Linear lichen planus Linear eczema (lichen striatus) | Non-lethal autosomal dominant gene | Half chromatid or somatic mutation |
| Linear dyspigmentation | Chromosomal abnormality | Somatic non-disjunction |
| Linear dyspigmentation | Normal | Chimerism |

abnormal maternal X in the pigmented skin as had been expected. This result was attributed to the proliferative advantage of cells containing the normal X.¹⁷ Most recently it has been tested in patients with chromosomal mosaicism and linear dyspigmentation. There are now many reports of cytogenetic studies on fibroblasts cultured from light and dark skin, but hardly any show pure cultures of the two different cell lines in the two different biopsies: there is almost always a mixture in one or both biopsies.¹¹⁻¹⁵

The most likely explanation for this is that fibroblasts do not conform to Blaschko's lines. Most of the dermatoses following Blaschko's lines (table 1) affect ectodermal derivatives, namely melanocytes, keratinocytes, or epidermal appendages. Similarly all the chimeric animal studies involve epidermal cells.⁴⁵ Therefore, we performed cytogenetic studies on cultured epidermal cells from light and dark areas of four patients with linear dyspigmentation, three of whom had severe neurological deficit (HI). We chose to examine keratinocytes rather than melanocytes simply because they are easier to grow.

Methods

CELL CULTURE AND CHROMOSOME ANALYSIS

Metaphase chromosome preparations were made from peripheral blood lymphocytes and cultured skin fibroblasts using standard methods.

For the preparation of keratinocytes for chromosome analysis the skin biopsies were washed in calcium and magnesium free PBS and then floated in 2 ml 0.1% trypsin solution for one hour at 37°C with agitation at 10 minute intervals, to separate the epidermis. The epidermis was then peeled back and the keratinocytes gently scraped from the keratin layer, and from the epidermal side of the basement membrane. The loose cells were collected by washing the tissue with medium and centrifuging the resultant cell suspension.

The cell yield was placed in a 60 mm petri dish containing 5×10^5 feeder cells (Swiss 3T3.J2 irradiated mouse fibroblasts) and K medium¹⁸ without epidermal growth factor (EGF). Mouse EGF (10 ng/ml) was added at the first medium change (three to four days) and at all subsequent changes. Cultures were incubated at 37°C in 10% CO₂ in air.

Primary cultures were subcultured after eight days' growth. The feeder layers were selectively removed by vigorous pipetting with 0.01% EDTA before disaggregating the keratinocytes with 1 part trypsin:1 part EDTA. Secondary cultures were established at 10^5 cells per 25 cm² growth area flasks prepared as for primary culture. Before harvesting for cytogenetics the feeder cells were again removed and metaphases prepared using standard methods.

PATIENTS

Case 1, an Asian female aged 3 years, had facial asymmetry, developmental delay, bilateral

sensorineural deafness, and hypopigmented streaks and whorls (fig 1). Previous cytogenetic studies in lymphocytes and in fibroblasts cultured from light and dark skin on the arm had been reported as normal with no mosaicism: a single fibroblast out of a total of 70 grown from dark skin showed the karyotype 46,XX, -13, +mar, but this was dismissed as a cultural artefact. Further 2 mm biopsies were taken from light and dark areas on the back for both fibroblast and keratinocyte culture.

Case 2, an Asian female aged 1 year, was developmentally delayed, epileptic, and severely visually impaired, with minimal white streaks on the right flank, hip, and leg (fig 2). Previous cytogenetic studies on lymphocytes were normal. Fibroblasts from a biopsy of light skin had failed to grow and from dark skin showed a normal karyotype. Further biopsies were taken from light and dark skin on the flanks for keratinocyte culture.

Case 3, a white male aged 13, had epilepsy, moderate learning difficulties with language, a webbed neck, bilateral talipes, and generalised light and dark streaks. Cytogenetic studies in lymphocytes and fibroblasts from light skin on the arm showed a normal 46,XY karyotype, while fibroblasts from adjacent dark skin showed a mixture of 46,XY and 45,X, 4.8% cells being abnormal. Further biopsies were taken from light and dark skin on the back for keratinocyte culture.

Case 4, a white male aged 13 years, was profoundly retarded and epileptic, with linear hypopigmented streaks. Lymphocytes had the karyotype 46,XY with no mosaicism. Biopsies were taken from light and dark skin on the arm for fibroblast and keratinocyte culture.

These fibroblast karyotypes are summarised in table 2.

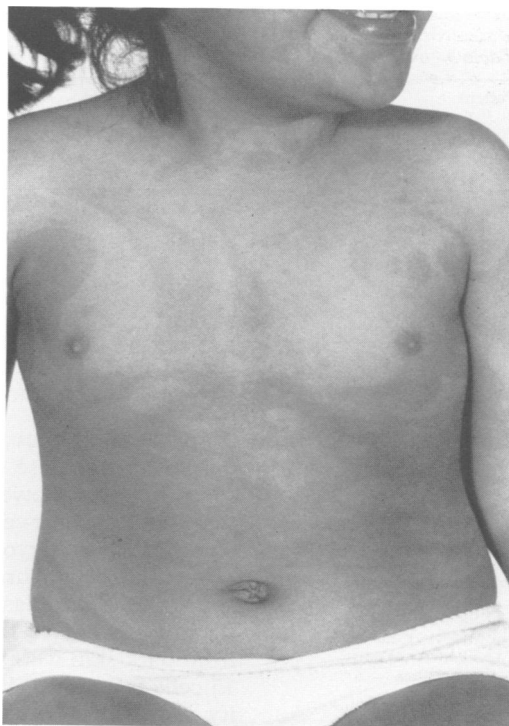

Figure 1 Hypopigmented streaks on the anterior trunk of case 1.

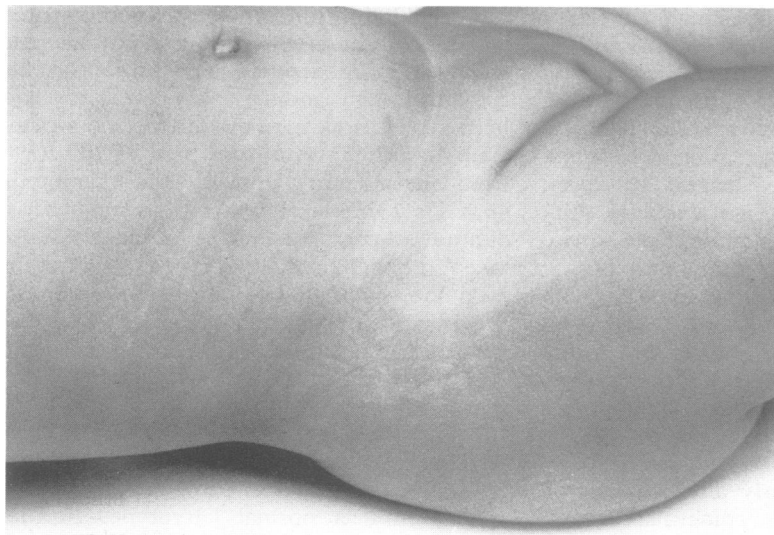


Figure 2 Hypopigmented streaks and whorl on the right hip and flank of case 2.

Table 2 Fibroblast karyotypes.

| Patient | Dark skin | | | Light skin | | |
|--------------------------|-----------|-------------|-----------------------------|------------|--------------|-----------------------------|
| | Cells | | Karyotype | Cells | | Karyotype |
| | No | % | | No | % | |
| Case 1 (1st culture) | 1 70 | 1.4 98.6 | 46,XX, - 13, + mar 46,XX | No growth | | |
| Case 1 (2nd culture)* | 35 | 100 | 46,XX | 2 13 | 13.3 86.7 | 46,XX, - 13, + mar 46,XX |
| Case 2 | 102 | 100 | 46,XX | No growth | | |
| Case 3 | 119 6 | 95.2 4.8 | 46,XY 45,X | 62 | 100 | 46,XY |
| Case 4 | 26 | 100 | 46,XY | 44 | 100 | 46,XY |

* Skin fibroblasts were cultured from case 1 on two occasions: the first time only fibroblasts were grown and the second time both fibroblasts and keratinocytes were grown.

Table 3 Keratinocyte karyotypes.

| Patient | Dark skin | | | Light skin | | |
|---------|-----------|-----|-----------|------------|-----|------------------|
| | Cells | | Karyotype | Cells | | Karyotype |
| | No | % | | No | % | |
| Case 1 | 15 | 100 | 46,XX | 4 | 100 | 46,XX, -13, +mar |
| Case 2 | 15 | 100 | 46,XX | 1 | 4 | 46,XX |
| | | | | 24 | 96 | 47,XX, +7 |
| Case 3 | 100 | 100 | 46,XY | 60 | 100 | 46,XY |
| Case 4 | 31 | 100 | 46,XY | 31 | 100 | 46,XY |

Results

Cytogenetic studies on keratinocytes showed the following. Case 1. All 15 cells examined from dark skin showed a normal 46,XX karyotype, while all four cells from light skin showed the abnormal karyotype 46,XX, -13, +mar, the small marker chromosome probably being a ring 13. Fibroblasts grown from the same skin biopsies gave the following: all 35 cells from dark skin were normal, while two out of 15 cells from light skin showed the abnormality 46,XX, -13, +mar. Case 2. All 15 cells from dark skin were normal (46,XX) while 24 out of 25 cells from light skin showed trisomy

7, one cell being normal. Case 3. All cells from both dark (100 cells) and light (60 cells) skin showed a normal 46,XY karyotype. Case 4. All cells from both dark and light skin showed a normal 46,XY karyotype.

These results are summarised in table 3.

Discussion

Our results show the following. (1) In chromosomally mosaic patients, keratinocytes cultured from light or dark skin demarcated by Blaschko's lines are more likely to yield a single cell type than are fibroblasts. Three of the eight successful fibroblast cultures yielded a mixture of cells, the abnormal cell line comprising 1.4 to 13.3% of cells examined. Only one of eight keratinocyte cultures yielded a mixture of cells, and in that culture only a single cell was 'out of place', having a normal karyotype when the other 24 cells had an extra chromosome 7. This could well be because of random loss in broken metaphase. These findings support the idea that Blaschko's lines demarcate epidermal rather than dermal clones. This idea is also supported by findings in the single patient where we looked at keratinocytes and fibroblasts from the same biopsy: the second skin biopsy from light skin in case 1 showed a mixture of cells in the dermis, but a pure culture in the overlying epidermis.

(2) In patients with dyspigmentation following Blaschko's lines, where chromosomal mosaicism is suspected but not definitely shown in fibroblasts, it may be confirmed in keratinocytes (cases 1 and 2). Clearly this observation will be useful clinically. The pathogenetic significance of this finding is not yet clear: our patients do not resemble previous patients with ring 13,¹⁹ 13q-,^{20,21} or trisomy 7,²² and this might be because of a low level of mosaicism or tissue specificity.

The finding of mosaicism in keratinocytes supports the idea that Blaschko's lines are determined by the epidermis, but the negative findings in two patients require explanation. In case 4 no mosaicism was found in any tissue, but this patient's phenotype is so typical of HI that it seems very likely that he is mosaic. It has been suggested that all patients with HI are mosaic but the mosaicism may be submicroscopic,²³ and this would certainly explain our negative findings in this patient. The result from case 3 was unexpected: keratinocytes from both light and dark skin showed a normal male karyotype, while fibroblasts from dark skin were mosaic 46,XY/45,X. The abnormal cells cannot be dismissed as artefactual because phenotypically the patient showed some features of Turner's syndrome, with a webbed neck and low posterior hairline. This finding can, however, be reconciled with the hypothesis that Blaschko's lines are determined by the epidermis, since keratinocytes are not the only cells in the epidermis: melanocytes are also present, and are obviously relevant in these patients because the phenomenon we are studying is pigmentation. In this patient, epidermal mosaicism might be confined to melanocytes, but this has

not yet been tested. Interestingly, case 3 was the most mildly affected neurologically of the patients we studied. Embryologically, keratinocytes and the central nervous system have the same ectodermal origin, while melanocytes derive later from the neural crest. We suggest that in this patient the abnormal cell line developed in the mesoderm and neural crest, largely sparing the keratinocytes and brain. We plan to test this hypothesis in future by examining cultured melanocytes for mosaicism.

(3) We predicted that in subjects with epidermal mosaicism, one skin type would show one cell line and the other skin type would show the other cell line. Our results have indeed shown this in case 1 and also in case 2 with the exception of only one cell.

(4) In both patients showing epidermal mosaicism, the abnormal (pale) skin contained the abnormal cell line. This revives the possibility that the cytogenetic abnormality is directly responsible for the failure of pigmentation. Previous studies in fibroblasts have shown abnormal cells in both light and dark skin: this observation, and the fact that so many different cytogenetic abnormalities produce the same appearance, has led to the idea that the pigmentary anomaly is a non-specific result of genetically different cells migrating together.²³ However, this does not explain the fact that most chromosomally mosaic patients do not have linear dyspigmentation. Furthermore, the control of pigment production, storage, and distribution is controlled by many genes,²⁴ and could probably be disturbed by many different chromosomal rearrangements in keratinocytes or melanocytes.

In conclusion, our limited findings support the idea that Blaschko's lines are determined by epidermal rather than fibroblast clones. We suggest that looking for chromosomal mosaicism is a more sensitive test for HI when carried out in keratinocytes rather than in fibroblasts alone, and in future melanocytes should also be studied. The presence of mosaicism in fibroblasts but not keratinocytes might be associated with a better prognosis neurologically. Finally, the cytogenetic abnormality

in the epidermis might be directly responsible for the failure of pigmentation in the pale streaks of hypomelanosis of Ito.

- 1 Blaschko A. Die Nevenverteilung in der Haut in ihrer Beziehung zu den Erkrankungen der Haut. *Beilage zu den Verhandlungen der Deutschen Dermatologischen Gesellschaft VII Congress, Breslau 1901*. Table 16. Wien, Leipzig: Braumüller, 1901.
- 2 Happle R. An early drawing of Blaschko's lines. *Br J Dermatol* 1993;128:464.
- 3 Montgomery DW. The cause of the streaks in naevus linearis. *J Cutaneous Genitourinary Dis* 1901;19:455-64.
- 4 Mintz B. Gene control of mammalian pigmentary differentiation. I. Clonal origin of melanocytes. *Proc Natl Acad Sci USA* 1967;58:344-51.
- 5 Schmidt GH, Blount MA, Ponder BAJ. Immunochemical demonstration of the clonal organisation of chimaeric mouse epidermis. *Development* 1987;100:534-41.
- 6 Curth HO, Warburton D. The genetics of incontinentia pigmenti. *Arch Dermatol* 1965;92:229-35.
- 7 Shuster S. *Dermatology in internal medicine*. Oxford: Oxford Medical Publications, 1978:21.
- 8 Happle R. Genetische Interpretation streifenförmiger Hautanomalien. *Hautarzt* 1978;29:357-63.
- 9 Happle R. Lyonization and the lines of Blaschko. *Hum Genet* 1985;70:200-6.
- 10 Happle R. Cutaneous manifestation of lethal genes. *Hum Genet* 1986;72:280.
- 11 Flannery DB, Byrd JR, Freeman WE, Perlman SA. Hypomelanosis of Ito: a cutaneous marker of chromosomal mosaicism. *Am J Hum Genet* 1985;37:A93.
- 12 Donnai D, Read AP, McKeown C, Andrews T. Hypomelanosis of Ito: a manifestation of mosaicism or chimerism. *J Med Genet* 1988;25:809-18.
- 13 Thomas IT, Frias JL, Cantu ES, et al. Association of pigmentary anomalies with chromosomal and genetic mosaicism and chimaerism. *Am J Hum Genet* 1989;45:193-205.
- 14 Flannery DB. Pigmentary dysplasias, hypomelanosis of Ito and genetic mosaicism. *Am J Med Genet* 1990;35:18-21.
- 15 Ohashi H, Tsukahara M, Murano I, et al. Pigmentary dysplasias and chromosomal mosaicism: report of nine cases. *Am J Med Genet* 1992;43:716-21.
- 16 Findlay GH, Moores PP. Pigment anomalies of the skin in human chimaera: their relation to systematised naevi. *Br J Dermatol* 1980;103:489-98.
- 17 Migeon B, Axelman J, de Beur SJ, et al. Selection against lethal alleles in females heterozygous for incontinentia pigmenti. *Am J Hum Genet* 1989;44:100-6.
- 18 O'Connor NE, Gallico GG, Compton C, et al. Grafting of burns with cultured epithelium prepared from autologous epidermal cells. II. Intermediate term results on three paediatric patients. In: Hunt TK, Heppenstall KB, Pines E, Rovee D, eds. *Soft and hard tissue repair*. Vol 2. Chapter 14. New York: Praeger, 1984:283-92.
- 19 Martin NJ, Harvey PH, Pearn JH. The ring chromosome 13 syndrome. *Hum Genet* 1982;61:18-23.
- 20 Tranebjaerg L, Nielsen KB, Tommerup N, et al. Interstitial deletion 13q: further delineation of the syndrome by clinical and high-resolution chromosome analysis of five patients. *Am J Med Genet* 1988;29:739-53.
- 21 Brandt CA, Hertz JM, Petersen MB, et al. Ring chromosome 13: lack of distinct syndromes based on different breakpoints on 13q. *J Med Genet* 1992;29:704-8.
- 22 Pflueger SMV, Scott CI, Moore CM. Trisomy 7 and Potter syndrome. *Clin Genet* 1984;25:543-8.
- 23 Read AP, Donnai D. Association of pigmentary anomalies with chromosomal and genetic mosaicism and chimaerism. *Am J Hum Genet* 1990;47:166-7.
- 24 Hearing VJ. Unraveling the melanocyte. *Am J Hum Genet* 1993;52:1-7.



Epidermal mosaicism and Blaschko's lines.

C Moss, S Larkins, M Stacey, A Blight, P A Farndon and E V Davison

J Med Genet 1993 30: 752-755

doi: 10.1136/jmg.30.9.752

Updated information and services can be found at:

<http://jmg.bmj.com/content/30/9/752>

These include:

Email alerting service

Receive free email alerts when new articles cite this article. Sign up in the box at the top right corner of the online article.

Notes

To request permissions go to:

<http://group.bmj.com/group/rights-licensing/permissions>

To order reprints go to:

<http://journals.bmj.com/cgi/reprintform>

To subscribe to BMJ go to:

<http://group.bmj.com/subscribe/>